Diseases of the Eccrine and Apocrine Sweat Glands

39

Jami L. Miller

Chapter Contents

Sweat Glands 641
Hyperhidrosis 641
Hypohidrosis and Anhidrosis 648
Abnormalities and Alterations of Eccrine and Apocrine Sweat Composition 650
Diagnostic Microscopic Changes in Eccrine Sweat Glands. 651
Influence of Sweat on Skin Diseases 651
Additional Disorders of the Eccrine Sweat Gland 651
Disorders of the Apocrine Sweat Gland 655

SWEAT GLANDS

Eccrine Sweat Glands

Key features

- 2–5 million eccrine glands are unevenly distributed over the skin surface
- In healthy individuals, eccrine sweat is 99% water
- Sweating is a reflex sympathetic autonomic function mediated by cholinergic neurons

In humans, sweating is essential for thermoregulatory homeostasis. There are two main mechanisms for cooling the body: radiative cooling via cutaneous vasodilation and evaporative cooling via sweat. Sweat, primarily produced by the eccrine sweat glands, leads to dissipation of heat through evaporation. Few mammals except humans and horses produce sweat in sufficient quantities to affect thermoregulation. For the purposes of this discussion, the term "sweat" applies to eccrine glands and their secretory products unless otherwise specified.

Although there are 2–5 million eccrine glands distributed within the skin, none are found on the clitoris, glans penis, labia minora, external auditory canal, or lips. Eccrine glands are separate from the apocrine–pilosebaceous apparatus, and by dermoscopy, eccrine ductal orifices can be seen along the dermatoglyphic ridges of the palms and soles. The average healthy adult can produce over 0.5 liters of sweat per hour, 99% of which is water. Athletes or those acclimatized to hot environments can produce up to 3–4 liters per hour[1]. Compared to other individuals, physically fit or acclimatized persons initiate sweating earlier and conserve sodium, chloride, and other electrolytes more efficiently. Thermoregulatory control is similar in men and women and diminishes only slightly with age[2].

Sweating is a reflex function controlled primarily by the sympathetic nervous system. These nerves are anatomically sympathetic but functionally cholinergic, i.e. acetylcholine, rather than norepinephrine, is the principal terminal neurotransmitter. Neural impulses for sweating (sudomotor impulses) travel from the anterior hypothalamus via the reticulospinal tracts to the appropriate level in the spinal cord, out through the rami communicantes to autonomic ganglia, and then within sympathetic cholinergic neurons to the secretory cells of the eccrine glands. Adrenergic innervation of eccrine glands has also been demonstrated, but is not believed to be physiologically important[3]. In addition, the sweat glands, via a direct effect on the secretory cells, respond to certain drugs (e.g. cholinergic agonists) as well as to the local application of heat.

Apocrine Sweat Glands

In humans, apocrine sweat glands are confined to the eyelids (Moll's glands), external auditory meatus, axillae, areola and nipple, periumbilical region, and anogenital region, in particular the mons pubis, labia minora, prepuce, scrotum, and perianal area. At five months' gestation, apocrine glands are distributed all over the body, whereas in a full-term neonate they are limited to the above sites. In non-primate mammals, apocrine sweat glands are widely distributed but they also open into the pilosebaceous unit.

Apocrine secretion is a slow, usually continuous process analogous to milk formation in the mammary gland. The secretory product is an oily fluid composed of lipids, proteins, and sex hormones. At or near the skin surface, it mixes with sebum derived from the sebaceous gland that empties into the same pilosebaceous unit.

HYPERHIDROSIS

Key features

- Excessive sweating
- Primary hyperhidrosis is the most common type, typically affecting the palms, soles, and/or axillae
- Secondary hyperhidrosis is due to an underlying condition (e.g. infection, tumor, genetic syndrome) or medication and may be localized or generalized

Hyperhidrosis is estimated to affect 3% of the US population[4]. The most widely used classification system divides it into primary (idiopathic) and secondary types. Other classification systems separate hyperhidrosis into categories based on the source of the neural impulses that drive it: cortical (emotional), hypothalamic (thermoregulatory), medullary (gustatory), spinal cord, and local axon reflexes.

Primary Hyperhidrosis

Synonym: ▪ Primary focal hyperhidrosis

Key features

- Main sites are volar (palms, soles) and axillary skin; the face may also be involved
- Hyperhidrosis arises from increased cortical stimulation and occurs *only* during waking hours (diurnal)
- Patients are otherwise healthy
- Up to 80% of affected individuals have a family history of hyperhidrosis

Primary hyperhidrosis, the most common type of hyperhidrosis, is defined as excessive sweating in localized areas (usually the palms, soles, and/or axillae) and is not associated with a systemic disorder.

Downloaded for Anonymous User (n/a) at Egyptian Knowledge Bank from ClinicalKey.com by Elsevier on March 10, 2024. For personal use only. No other uses without permission. Copyright ©2024. Elsevier Inc. All rights reserved.

Men and women of all races are equally affected. Table 39.1 lists the diagnostic criteria[5]. Between 60% and 80% of patients with primary hyperhidrosis have a family history[6], with a pattern of inheritance suggesting autosomal dominant transmission with incomplete penetrance. A locus for primary palmar hyperhidrosis was mapped to chromosome 14q in three Japanese families[7].

Intense emotion or stress can elicit sweating in anyone. It occurs most often on the palms, soles, or axillae and can also affect the face (Fig. 39.1), especially the forehead and the cutaneous upper lip. The post-orgasmic sweating observed with sexual activity may also derive from emotional stimulation[8].

Clinically significant primary hyperhidrosis occurs in two major patterns: volar (palmoplantar) and axillary, which can coexist[1], but usually one of the two sites predominates. The onset of volar hyperhidrosis is often during childhood, whereas axillary hyperhidrosis typically develops at or soon after puberty. Primary hyperhidrosis is seen in both cold and warm environments. A chronic and unremitting course is characteristic, with little or no variation in association with age, disease, or hormonal status.

Volar hyperhidrosis is the most common form of primary hyperhidrosis (Fig. 39.2), affecting ~50%–60% of patients[3,4]. The entire palm and sole, as well as the lateral aspects, tips and distal dorsal skin of the fingers, display sweating. It can clearly have an impact on quality of life.

Axillary hyperhidrosis is the second most common form of primary hyperhidrosis, affecting 30%–50% of patients[4]. The right axilla usually produces more sweat than the left (60 : 40). Exceptionally, one axilla may be hyperhidrotic while the opposite axilla is hypohidrotic or virtually anhidrotic. Odor (axillary bromhidrosis) is usually absent; the excessive quantities of eccrine sweat presumably rinse away or dilute odorogenic apocrine sweat droplets and bacteria.

Secondary Hyperhidrosis

Secondary hyperhidrosis is caused by or associated with another systemic disorder. It may be localized or generalized. There are many causes, which can be divided into categories based on the source of the neural impulse driving the response: cortical, hypothalamic, medullary, spinal cord, or local. A number of medications may also be associated with hyperhidrosis (Table 39.2).

Disorders associated with cortical (emotional) hyperhidrosis

Key features

- Several disorders of cornification and other genodermatoses affecting palmoplantar skin are associated with volar hyperhidrosis
- Patients with hereditary autonomic neuropathies can also exhibit cortical hyperhidrosis

Isolated sweating of the palms and soles is primarily due to cortical excitation by emotional or sensory stimuli. Excessive volar sweating associated with certain inherited palmoplantar keratodermas is assumed to be cortical in nature, although the pathogenic relationship between the abnormal keratinization and hyperhidrosis has not been precisely delineated. Many palmoplantar keratodermas are malodorous, likely related to sweat-induced maceration of the thickened stratum corneum and bacterial degradation of keratin. Other genodermatoses affecting the volar skin, such as epidermolysis bullosa simplex, can also have associated palmoplantar hyperhidrosis. Additional causes of cortical hyperhidrosis are listed in Table 39.3.

CRITERIA FOR THE DIAGNOSIS OF PRIMARY HYPERHIDROSIS
1. Focal, visible excess sweating
2. Present for at least 6 months
3. No apparent secondary causes
4. At least two of the following:
• Bilateral and symmetric
• Impairs activities of daily life
• At least one episode per week
• Age of onset <25 years
• Positive family history
• Stops during sleep

Table 39.1 Criteria for the diagnosis of primary hyperhidrosis. *Adapted from Hornberger J, Grimees K, Naumann M, et al. Recognition, diagnosis and treatment of primary focal hyperhidrosis. J Am Acad Dermatol 2004;51:274–86.*

Fig. 39.1 Primary cortical (emotional) hyperhidrosis involving the face. Sweat droplets are evident on the upper cutaneous lip, jawline, and chin. *Reproduced from Hurley HJ. Hyperhidrosis. Curr Opin Dermatol 1997;4:105–14. Philadelphia: Rapid Science Publishers.*

Fig. 39.2 Volar hyperhidrosis (primary cortical). A, B The plantar skin is moist and glistening with eccrine sweat. There are also sweat droplets. *Courtesy Jean L. Bolognia, MD.*

Downloaded for Anonymous User (n/a) at Egyptian Knowledge Bank from ClinicalKey.com by Elsevier on March 10, 2024. For personal use only. No other uses without permission. Copyright ©2024. Elsevier Inc. All rights reserved.

DRUGS THAT CAN STIMULATE ECCRINE SWEATING	
Direct-acting cholinomimetic agents	
• Acetylcholine	• Anti-xerostomia drugs (see Table 45.5)
Cholinesterase inhibitors	
• Anti-Alzheimer drugs* • Anticholinergic antidote	• Antimyasthenics
Adrenomimetic agents	
• Dopamine • Epinephrine (adrenaline) • Isoproterenol	• Norepinephrine (noradrenaline) • Phenylpropanolamine
Antidiabetic (hypoglycemic) agents	
• Insulins	• Sulfonylureas
• Biguanides	
CNS stimulants	
• Amphetamines • Caffeine	• Theophylline
Antidepressants	
• MAOIs† • SSRIs†	• Tricyclics†
Antipsychotics	
Antipyretics	
Opioids	
Other drugs	
• ACE inhibitors • Amlodipine • Atomoxetine • Dextromethorphan*,† • Ipecac • Pentoxifylline	• Phosphodiesterase inhibitors (e.g. sildenafil) • Sibutramine† • Sumatriptan† • Tramadol† • Yohimbine

*Increased sweating is infrequently observed at pharmacologic doses but represents a sign of overdose.
†Combination of MAOIs (which include linezolid as well as antidepressants) with drugs such as tricyclics, SSRIs, certain opioids, and tryptophan can result in the serotonin syndrome; the latter is characterized by mental status changes, autonomic hyperactivity (including hyperhidrosis), and neuromuscular abnormalities.

Table 39.2 Drugs that can stimulate eccrine sweating. Selective estrogen receptor modulators (e.g. tamoxifen, raloxifene) and aromatase inhibitors (e.g. anastrozole) can lead to menopausal symptoms including hot flashes with sweating. ACE, angiotensin-converting enzyme; CNS, central nervous system; MAOI, monoamine oxidase inhibitor; SSRI, selective serotonin reuptake inhibitor.

CAUSES OF CORTICAL (STRESS/EMOTIONAL) HYPERHIDROSIS
Primary hyperhidrosis (see Table 39.1)
Secondary hyperhidrosis
Disorders of cornification
• Palmoplantar keratodermas • Pachyonychia congenita • Congenital ichthyosiform erythroderma and epidermolytic ichthyosis
Other genodermatoses
• Epidermolysis bullosa: simplex > junctional • Dermatopathia pigmentosa reticularis • Dyskeratosis congenita • Pachydermoperiostosis (digital clubbing and thick, furrowed skin on the face and scalp) • Apert syndrome (craniosynostosis, digital anomalies, severe acne; *FGFR2* mutations) • Nail–patella syndrome
Hereditary sensory and autonomic neuropathies (HSANs)*
• Familial dysautonomia (Riley–Day syndrome; HSAN type III; blotchy erythema accompanies episodic hyperhidrosis of the face and trunk, decreased lacrimation, postural hypotension, and dysautonomic crises [vomiting, hypertension]) • Congenital autonomic dysfunction with universal pain loss • Congenital sensory neuropathy (HSAN type II)
*Hypothalamic (thermal) hyperhidrosis can also occur.

Table 39.3 Causes of cortical (stress/emotional) hyperhidrosis. *Adapted from Moschella S, Hurley HV. Dermatology. Philadelphia: WB Saunders, 1992.*

Hypothalamic (thermoregulatory) hyperhidrosis

Key features

- Due to elevated body temperature (e.g. acute febrile illness, lymphoma, chronic infection) or direct hypothalamic stimuli (e.g. pheochromocytoma, medications, toxins)
- May be nocturnal (night sweats) or diurnal

The hypothalamus is responsible for many autonomic activities, including thermoregulation. Elevation of the temperature of the blood by 0.5°F (0.3°C) or more excites the hypothalamic nuclei and results in vascular dilation and generalized sweating responses aimed at dissipating body heat[3].

Febrile illnesses are among the most common pathologic states that cause hypothalamic sweating. At the height of the fever, notably with temperatures of 39–40°C (102–104°F) or above, sweating is absent, the apparent result of inhibition of the hypothalamic center for sweating. With defervescence, sweating characteristically ensues. Lymphomas and chronic infections (e.g. tuberculosis) can present with episodic thermoregulatory sweating, which may be described as "night sweats" (that actually follow unperceived mild febrile pulses).

Generalized sweating of hypothalamic origin can also be seen in a number of metabolic and endocrine disorders (Table 39.4). Patients with diabetes mellitus may exhibit hypohidrosis as well as various forms of hyperhidrosis. For example, hyperhidrosis is a characteristic sign of insulin-induced hypoglycemia (but not diabetic ketoacidosis), and compensatory hyperhidrosis of the trunk can develop in the setting of diabetic neuropathy affecting the extremities (see below). In addition, diabetics may exhibit gustatory hyperhidrosis, primarily of the face and neck. Troublesome sweating of the scalp can also be seen in poorly controlled diabetics, and, with regulation of the hyperglycemia, it often improves.

Disorders with vasomotor instability, such as Raynaud phenomenon, autoimmune connective tissue diseases, frostbite and other cold injuries, and complex regional pain syndrome, may be associated with excessive sweating because of disturbed autonomic function[9]. A synchronous discharge of vasoconstrictor and sudomotor impulses evokes a "cold sweat", usually of the hands and feet, producing macerated, soggy wet, violaceous skin known as symmetrical lividity.

Cerebral cortex lesions, such as a tumor, abscess or cerebrovascular accident, may be associated with a contralateral hyperhidrosis due to an impairment of the inhibitory cortical influence that normally regulates hypothalamic sudomotor activity[10]. Hypothalamic sweating is also observed in Parkinson disease and occurs as the "sweating sickness" following encephalitis. Harlequin syndrome, characterized by unilateral flushing and hyperhidrosis in association with contralateral anhidrosis, may be due to peripheral or central nervous system (CNS) abnormalities[11].

Episodic release of catecholamines from pheochromocytomas directly stimulates the hypothalamus and may elicit sweating[12]. Exposures to toxins and medications can also lead to hypothalamic hyperhidrosis, and a number of drugs that act on the CNS have increased sweating as a potential side effect (see Table 39.2). Additional causes of hypothalamic hyperhidrosis are presented in Table 39.4.

Pressure and postural hyperhidrosis may be due to hypothalamic or possibly cortical stimulation. With changes in posture or the application of pressure to one side of a supine individual, a variety of sweating patterns have been described, such as lateral hyperhidrosis, horizontal hemihidrosis, and crossed hemihidrosis. Idiopathic localized unilateral hyperhidrosis of the face and neck or forearm has been reported as an episodic disorder triggered by heat, emotional, or gustatory stimuli[13].

Downloaded for Anonymous User (n/a) at Egyptian Knowledge Bank from ClinicalKey.com by Elsevier on March 10, 2024. For personal use only. No other uses without permission. Copyright ©2024. Elsevier Inc. All rights reserved.

CAUSES OF HYPOTHALAMIC HYPERHIDROSIS						
Infection	**Tumors**	**Endocrine/ metabolic**	**Vasomotor**	**Neurologic**	**Drugs/ toxins**	**Miscellaneous**
• Acute febrile illnesses (defervescence) • Tuberculosis • Brucellosis • Malaria • Subacute bacterial endocarditis • Other	• Lymphoma • Pheochromocytoma* • Carcinoid*	• Menopause • Hypoglycemia • Obesity • Hyperthyroidism • Acromegaly • Pregnancy • Porphyria (acute intermittent) • Phenylketonuria • Gout	• Congestive heart failure† • Myocardial ischemia • Raynaud phenomenon • Acrocyanosis • Cold injury • Symmetrical lividity of the palms and soles‡ • Complex regional pain syndrome • Autoimmune connective tissue disease (e.g. rheumatoid arthritis, SLE)	• CNS tumors • Cerebrovascular accidents • Parkinson disease • Postencephalitic • Episodic spontaneous hypothermia with hyperhidrosis§ • Cold-induced sweating syndrome‖ • Familial dysautonomia‡	• Alcoholism • Alcohol or opioid withdrawal • SERMs and aromatase inhibitors • Mercury toxicity (acrodynia) • Chronic arsenic toxicity • See Table 39.2	• Compensatory hyperhidrosis (e.g. in association with miliaria, diabetic neuropathy, sympathectomy)¶ • Localized unilateral hyperhidrosis (face and neck, forearm)‡ • POEMS syndrome • Speckled lentiginous nevus syndrome • Mitochondrial disorders • Pressure and postural hyperhidrosis‡

*Via release of catecholamines (pheochromocytoma) or serotonin (carcinoid tumors, usually metastatic; see Ch. 106).
†Patients have sympathetic activation, with impaired vasodilatory responses to heating but preserved sweating.
‡Also associated with cortical hyperhidrosis.
¶Compensatory hyperhidrosis is also a feature of Ross syndrome (segmental anhidrosis, generalized areflexia and tonic pupils).
§Referred to as Hines–Bannick syndrome or, when associated with agenesis of the corpus callosum, Shapiro syndrome.
‖Autosomal recessive condition caused by mutations in the genes encoding cytokine receptor-like factor-1 and cardiotrophin-like cytokine factor-1; additional features include facial dysmorphism, flexion deformities (elbows, fingers), and scoliosis.

Table 39.4 Causes of hypothalamic hyperhidrosis. SERMs, selective estrogen receptor modulators; SLE, systemic lupus erythematosus. *Adapted from Moschella S, Hurley HV. Dermatology. Philadelphia: WB Saunders, 1992.*

Medullary (gustatory) hyperhidrosis

Key features

- Taste receptors in the mouth are the source of the afferent impulses that stimulate sweating
- *Physiologic* medullary hyperhidrosis is most commonly triggered by spicy foods, alcohol, and citrus fruits
- *Pathologic* medullary hyperhidrosis occurs when disrupted nerves for sweat aberrantly connect with nerves for salivation; this can be caused by local injury to, or disease of, the parotid gland (Frey syndrome), trauma to the sympathetic trunk, and CNS disorders (e.g. encephalitis, syringomyelia)

Physiologic medullary hyperhidrosis

Any food or drink that stimulates the taste buds may induce sweating in normal individuals, particularly of the face. This is thought to occur via a variant reflex arc in which afferent impulses from taste bud receptors travel via the glossopharyngeal nerve to nuclei within the medulla oblongata (hence the term "medullary" hyperhidrosis), but lead to provocation of sweating rather than (or in addition to) the usual response of salivation. A few minutes after ingestion of a stimulating food or beverage, sweating and erythema are seen most commonly on the upper cutaneous lip or cheeks. It may be unilateral or bilateral and may be brief or persist as long as the stimulating food or beverage is ingested. Associated vasodilation localized to the areas of sweating causes the erythema, which may be faint. Spicy or sharp-tasting foods and beverages, such as citrus fruits, alcohol and condiments, may elicit the reaction. It is most common in children and young adults and in warmer environments. A familial tendency has been described[14]. There are no other concurrent local or systemic signs or symptoms. A variant of gustatory hyperhidrosis can occur on the face in diabetics. Unusual types of gustatory hyperhidrosis involving the scalp and the knee have also been described and support the concept of a central medullary mechanism for these sweating responses[15].

Pathologic medullary hyperhidrosis

This disorder arises after disruption of nerves. During healing, nerve fibers mediating sweating aberrantly connect to nerves that mediate salivation. Impulses in parasympathetic fibers normally supplying the salivary glands are now misdirected to the sweat glands. As a result, salivary stimulation elicits sweating. Of note, thermal sweating in the areas of affected skin is reduced.

The parotid form appears weeks to months following a surgical procedure, trauma, or other disorder (e.g. abscess, herpes zoster) affecting the parotid gland. These patients experience vasodilation and sweating on the cheek and adjacent neck when salivary stimulation is induced by eating, drinking, or even chewing (Fig. 39.3). Sweating most often occurs in the distribution of the auriculotemporal nerve; at times there is also unilateral localized pain[16].

Auriculotemporal syndrome (Frey syndrome) is common after parotid surgery, developing in 40% or more of patients, although many

Fig. 39.3 Gustatory sweating in the auriculotemporal (Frey) syndrome, as a consequence of parotid surgery. The blue–black area represents sweating (starch–iodine technique). Salivary stimulation induced this sweating response. *Reproduced from Hurley HJ. Hyperhidrosis. Curr Opin Dermatol 1997;4:105–14. Philadelphia: Rapid Science Publishers.*

Downloaded for Anonymous User (n/a) at Egyptian Knowledge Bank from ClinicalKey.com by Elsevier on March 10, 2024. For personal use only. No other uses without permission. Copyright ©2024. Elsevier Inc. All rights reserved.

are not aware of it. It can also occur during infancy, frequently as a consequence of trauma to the parotid region in a forceps-assisted delivery. The infant presents with gustatory flushing, but usually no obvious sweating, and this is often erroneously attributed to food allergy. Another variant of gustatory hyperhidrosis is the chorda tympani syndrome in which salivary stimuli to the submandibular gland induce sweating on the chin and lower jaw line.

Patients with cluster headaches can have sympathetic deficits that result in impaired thermoregulatory sweating on the affected side of the forehead. In addition, ipsilateral hyperhidrosis and flushing may occur, together with excessive lacrimation, during headache attacks. This is due to misdirection of parasympathetic fibers, which normally supply the lacrimal glands, to sweat glands and blood vessels. Patients with Raeder syndrome (Horner syndrome [ptosis, meiosis ± anhidrosis] plus unilateral temporofrontal headaches and pain) may also have excessive supraorbital sweating, also referred to as lacrimal sweating.

Any condition that injures the vagus nerve and sympathetic trunk, as they lie close together in the thorax, may cause pathologic medullary hyperhidrosis (Table 39.5). Cholinergic fibers from the vagus nerve sprout into the adjacent sympathetic trunk during the healing process and can result in a gustatory hyperhidrosis with sweating on the face, neck, and portions of the trunk and upper extremities.

In patients with syringomyelia or encephalitis, gustatory hyperhidrosis is occasionally seen on the face and upper trunk. It involves the glossopharyngeal and vagus nerves. Disturbances in the brainstem apparently lead to transposition of the central medullary nuclei for salivation and sweating. There is no peripheral crossing of sympathetic and parasympathetic nerve fibers as is seen in other forms of pathologic gustatory hyperhidrosis.

Spinal (cord transection) sweating

Key features

- Spinal disorders may result in a lack of thermal sweating below the injury as well as unusual patterns of hyperhidrosis
- Mass reflex sweating may occur around the injured level

Any injury or disease process that severs or interferes with the reticulospinal tracts of the cord can disrupt the sweating reflex (see Table 39.5). Lack of a sweat response to thermal stimulation usually occurs below the level of the injury. Abnormal patterns of segmental sweating may occur in conjunction with other autonomic, sensory, and motor alterations. Onset and duration are unpredictable. Sweating can be excessive, drenching the patient in the regions involved. Bouts of "mass reflex sweating" are initiated in the skin below the level of the cord interruption. It is most intense in skin segments close to the level of the transection. Mass reflex sweating does not occur in transections below T8–T10.

Autonomic dysreflexia

Key features

- Direct stimulation (e.g. electrical, physical, or drug-induced) of a sympathetic axon can cause sweating
- May be seen with inflammatory skin diseases

Autonomic dysreflexia is a syndrome that may occur with spinal injuries at or above T6[17]. Massive episodic sympathetic discharge results in sweating above the level of the transection accompanied by headache, hypertension, facial flushing, bradycardia or tachycardia, piloerection, and paresthesias.

Direct stimulation of a cutaneous sympathetic axon with electrical and physical impulses or injections of drugs with nicotine-like effects on autonomic ganglia can induce sweating in an area ~4 cm in diameter[3]. Mediators from inflammatory skin conditions (e.g. psoriasis, dermatitis) can also elicit localized hyperhidrosis. Substance P and a number of other mediators, including kinins, dopamine, prostaglandins, angiotensin and adenine, may be involved[18].

Compensatory hyperhidrosis

Key features

- Anhidrosis in one area may cause hyperhidrosis in another
- Miliaria, diabetic neuropathy, and sympathectomy are well-known causes

The coordinated functioning of the body's eccrine sweat glands is illustrated by the phenomenon of compensatory hyperhidrosis, in which the sweat glands of one area become hyperactive in an effort to compensate for hypo- or anhidrosis in another. Apparently, a threshold number of sweat glands must be non-functional in order for the compensatory response to occur. The nature or type of the underlying process that produces the anhidrosis also appears to be important. For example, compensatory hyperhidrosis does not seem to develop secondary to the anhidrosis produced by lymphomas.

The best-known clinical forms of compensatory hyperhidrosis occur in the following three situations:

- *Miliaria*: longstanding or recurrent miliaria rubra or profunda typically results in numerous non-functional sweat glands within large areas of the trunk. This induces compensatory hyperhidrosis of the face (Fig. 39.4A), especially in response to ambient heat or exercise.
- In *diabetes mellitus*, disturbance of the autonomic nervous system due to peripheral neuropathy and microangiopathy often causes anhidrosis or hypohidrosis of the affected skin, particularly the legs. With the loss of sweating on the lower extremities, these patients may develop compensatory increases in thermal sweating on the trunk, especially the back. A second type of compensatory

OTHER CAUSES OF SECONDARY HYPERHIDROSIS			
Medullary (gustatory)	**Spinal cord**	**Axon reflex**	**Abnormal blood vessels or eccrine glands (non-neural)**
• Physiologic gustatory sweating • Frey syndrome • Chorda tympani syndrome • Cluster headaches • Sympathectomy • Sympathetic trunk and vagus nerve injury (e.g. by lung carcinoma, mesothelioma, thyroidectomy, subclavian aneurysm) • Encephalitis • Syringomyelia	• Spinal injury • Syringomyelia • Tabes dorsalis	• Inflammatory skin diseases • Drugs (see Table 39.2)	• Aquagenic palmoplantar keratoderma (see Fig. 58.19) • Eccrine nevi • Eccrine angiomatous hamartoma (see Fig. 39.5) • Maffucci syndrome • Arteriovenous fistula • Klippel–Trenaunay syndrome • Glomuvenous malformation • Blue rubber bleb nevus syndrome • Cold erythema • Granulosis rubra nasi • Pretibial myxedema

Table 39.5 Other causes of secondary hyperhidrosis. Gustatory lacrimation ("crocodile tears" syndrome) is due to transposition of autonomic fibers for lacrimation and salivation after facial nerve injury. *Adapted from Moschella S, Hurley HV. Dermatology. Philadelphia: WB Saunders, 1992.*

Downloaded for Anonymous User (n/a) at Egyptian Knowledge Bank from ClinicalKey.com by Elsevier on March 10, 2024. For personal use only. No other uses without permission. Copyright ©2024. Elsevier Inc. All rights reserved.

hyperhidrosis, gustatory in character and usually on the face and neck (Fig. 39.4B), may also be seen in diabetic patients with peripheral neuropathy of the lower extremities.

- *Post-sympathectomy*: with the loss of sweating that results from cervicothoracic sympathectomies, a thermal hyperhidrosis, usually on the trunk, is common. Sympathectomized patients may also experience gustatory hyperhidrosis.

Non-neural hyperhidrosis

Key features

- Direct stimulation of eccrine glands can cause sweating
- Triggers include local heat, drugs, and vascular tumors

Direct stimulation of eccrine sweat glands by heat or sudomimetic drugs can lead to localized sweating. Even denervated skin sweats when heat is applied[3]. Table 39.5 outlines additional non-neural causes of localized hyperhidrosis (Fig. 39.5). The rare disorder "cold erythema" affects the skin and gastrointestinal tract – exposure to cold produces local cutaneous erythema and intense pain along with a central area of hyperhidrosis. As with other entities in which local pain is a clinical feature (e.g. glomuvenous malformations), increased blood flow or an axon reflex (secondary to the pain) may be the causal mechanism for this sweating.

Diagnosis of Hyperhidrosis

Key features

- Differentiation between primary and secondary hyperhidrosis is important
- Hyperhidrosis can be documented by colorimetric and gravimetric methods

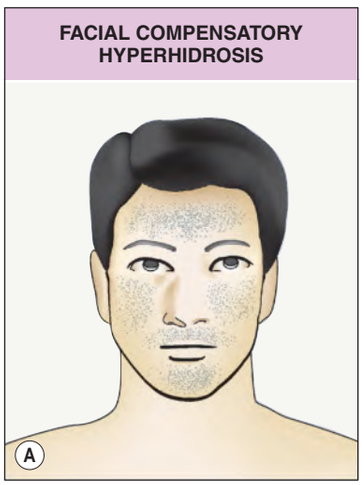

Fig. 39.4 Compensatory hyperhidrosis of the face. A Outline of the sites of facial compensatory hyperhidrosis in patients with extensive miliaria. **B** Facial compensatory hyperhidrosis (upper lip and chin) in a patient with diabetes mellitus (starch–iodine technique). *Courtesy Harry Hurley, MD.*

The first step is to differentiate between primary and secondary hyperhidrosis. History will elicit location, duration, and specific triggers. Other medical disorders and medications (including over-the-counter products) need to be ascertained. An extensive review of systems should point to any secondary causes.

Patients who do not fit the classic pattern of primary hyperhidrosis (see Table 39.1) should undergo further evaluation, focusing on possible etiologies (see Tables 39.2–39.5) during a complete history and physical examination. Laboratory testing and radiographic studies may be needed (Table 39.6).

Measurement of sweat can be performed. A grading scale for volar disease lists "low" as a moist palm or sole without visible sweat droplets. "Moderate" disease is characterized by sweating toward the fingertips. "Severe" cases drip sweat. Axillary involvement can be measured by the sweat stains on clothing: <5 cm is considered normal; 5–10 cm, mild; 10–20 cm, moderate; and >20 cm, severe.

Colorimetric techniques such as the starch–iodine or quinizarin methods demonstrate the sweating pattern and reveal the location of the most active sweat glands in a given area[19]. In the starch–iodine technique, iodine solution (e.g. 3.5% in alcohol) is applied to clean, shaved skin and allowed to dry. Starch powder (e.g. cornstarch) is then brushed onto the area. Sites with sweating turn blue–black (Fig. 39.6). A combination of iodine and paper impregnated with starch can also be utilized (Fig. 39.7).

Additional quantitative assessment methods are available. In order to document amounts of sweat produced, gravimetric (via weighing filter paper before and after application to the skin) and evaporative (via a device that assesses water vapor loss from the skin) measurements can be made in volar or axillary sites[19]. Infrared thermography and skin conductance measurements represent other methods of evaluating sweat gland function, allowing comparison between anatomic areas and even individual glands.

Treatment of Hyperhidrosis

Key feature

- Treatment options for hyperhidrosis include topical sweat duct blockers, topical glycopyrronium, sweat-reducing oral medications, botulinum toxin, iontophoresis, biofeedback therapy, microwave thermolysis, and surgical procedures

Treatment options available for hyperhidrosis are outlined in Table 39.7. Over-the-counter products include antiperspirants and deodorants; the latter contain antimicrobial agents while both contain odor-masking fragrances. The major active ingredient in topical antiperspirants is

Fig. 39.5 Eccrine angiomatous hamartoma. Cluster of painful pink–violet papules and plaques on the thigh and knee that had been present since one year of age. There was associated hyperhidrosis, but not hypertrichosis. Histologically, an increased number of both eccrine glands and small blood vessels is seen. *Courtesy Julie V. Schaffer, MD.*

Downloaded for Anonymous User (n/a) at Egyptian Knowledge Bank from ClinicalKey.com by Elsevier on March 10, 2024. For personal use only. No other uses without permission. Copyright ©2024. Elsevier Inc. All rights reserved.

INITIAL PATIENT EVALUATION FOR SECONDARY HYPERHIDROSIS	
Laboratory test	**Disease**
Serum electrolytes, BUN, creatinine	Renal disease (rare)
Fasting blood glucose level and/or HbA1c	Diabetes mellitus
Thyroid function tests	Hyperthyroidism
Skin and/or blood tests for tuberculosis (e.g. PPD, QFTB-G)	Tuberculosis
Chest X-ray	Tuberculosis, neoplasm (e.g. lymphoma)
Complete blood count	Infection
Sedimentation rate/C-reactive protein test	Infection, neoplasm, inflammatory disease
Antinuclear antibodies	Autoimmune connective tissue disease
Urinary catecholamines*	Pheochromocytoma
*If suggestive signs or symptoms (see Ch. 106).	

Table 39.6 Initial patient evaluation for secondary hyperhidrosis. Further evaluation depends upon results and consideration of entities in Table 39.4. BUN, blood urea nitrogen; PPD, (tuberculin) purified protein derivative; QFTB-G, QuantiFERON-TB Gold.

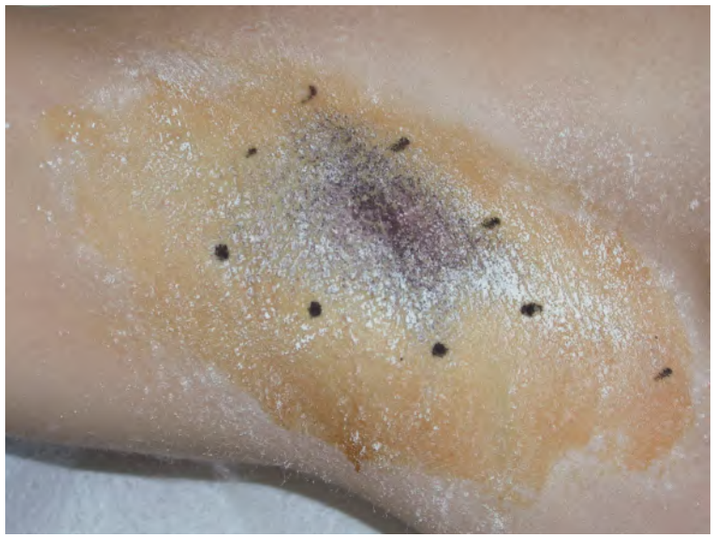

Fig. 39.6 Delineation of area for injections of botulinum toxin A for axillary hyperhidrosis (starch–iodine technique). The blue–black area represents foci of sweating (reflected in black dots). In the case of onabotulinumtoxinA, a total of 50–100 U is injected within this area, utilizing 10 to 15 injection sites. *Courtesy Alastair Carruthers, MD, and Jean Carruthers, MD.*

metal (usually aluminum) salts which deposit within and temporarily block the sweat duct. Prescription antiperspirants contain higher concentrations of these salts. They should be applied to dry surfaces at night, when sweating is diminished. Occlusion enhances penetration of the salts. Application is recommended for three to five consecutive nights, then one to two times a week as needed to control sweating. Treated skin can be washed the following morning. Burning and irritant contact dermatitis are common side effects, particularly in women who shave their axillae and with higher salt concentrations.

Some patients who sweat significantly at night require a preliminary dose of an anticholinergic drug 1 hour before application for the first few applications (see below). This reduces sweating enough to prevent the topical solution from being rinsed away. Topical aldehyde agents such as formaldehyde and glutaraldehyde are effective, but allergic sensitization may develop that can result in cross-reactions with aldehydes in the environment (lotions, soaps, shoes).

Daily topical application of glycopyrronium tosylate via a cloth towelette is FDA-approved for the treatment of primary axillary hyperhidrosis in individuals nine years of age or older. After four weeks, 60% of treated

Fig. 39.7 Palmar hyperhidrosis as assessed by the semiquantitative starch paper–iodine technique. Sweating can also be demonstrated directly on palmar skin by the starch–iodine technique, as shown in Fig. 39.6 for axillary hyperhidrosis. *Courtesy Harry Hurley, MD.*

patients reported a significant reduction in sweat severity compared to 28% of those who applied the alcohol-based vehicle[20]. Botulinum liposomal cream and topical oxybutinin gel have also shown efficacy but currently are not commercially available. Table 39.7 outlines anticholinergic-related side effects. Patients with diseases that can be exacerbated by anticholinergics (e.g. glaucoma, myasthenia gravis, Sjögren syndrome, severe ulcerative colitis) should avoid their use.

Tap water iontophoresis over 20 minutes two to three times a week may be helpful. The mechanism of action is unknown but is thought to lead to blockage of the sweat duct in the stratum corneum. Side effects are minimal and include tingling of the skin during treatment. Introduction of anticholinergic medications via iontophoresis is not advised due to potential systemic absorption.

Oral anticholinergics will decrease sweating in most patients. The most commonly used agents are oxybutynin[21] and glycopyrrolate[22] (see Table 39.7 for recommended regimens). When higher doses are required to control the hyperhidrosis, unacceptable side effects can often develop, including dry eyes and mouth, insomnia, mental status changes (e.g. confusion, hallucinations), palpitations, seizures, blurred vision, bowel disturbances, urinary retention, and hypertension. More recently, a link between the long-term use of oral anticholinergic medications and development of dementia has been reported. As a result, limiting the duration of exposure to these medications has been recommended[23], and the use of calcium channel blockers as an alternative has increased.

Clonidine (an α_2-adrenergic agonist that decreases central sympathetic outflow) and phenoxybenzamine (an α-adrenergic blocker) have been used with some success in anecdotal reports[24,25]. Potential side effects include hypotension, rebound hypertension, sedation, constipation, weakness, and headache. Propranolol, a β-adrenergic blocker, is commonly used for the treatment of performance anxiety and it may improve hyperhidrosis temporarily. However, long-term use may induce hyperhidrosis.

OnabotulinumtoxinA (BTA) has been approved by the FDA for the treatment of severe axillary hyperhidrosis (see Fig. 39.6); it is also effective for volar disease. Botulinum toxins prevent the release of acetylcholine from cholinergic neurons (see Ch. 159). Injection into hyperhidrotic skin will produce near anhidrosis for 4 to 6 months (see Video 159.7). Side effects, if any, are short-lived. Muscle weakness, especially of the intrinsic muscles of the hands or feet, has been reported and resolves spontaneously over 2 to 5 weeks. Compensatory hyperhidrosis has not been observed[26]. Botulinum toxin injections should be avoided in patients who have pre-existing muscle weakness due to disorders such as myasthenia gravis and amyotrophic lateral sclerosis. To date, other botulinum toxins have not been FDA-approved for hyperhidrosis (see Table 159.1).

Surgical treatment may be offered if other therapeutic modalities have failed. Destruction of sweat glands by lasers[26], fractional microneedle radiofrequency, or microwave thermolysis can be performed[27]. Surgical dissection[28], curettage, or liposuction represent additional treatment options[29]. Excision of the sweat glands is often effective for axillary disease, but resection of the entire axillary skin causes significant scarring. However, compensatory hyperhidrosis is not seen with this form of local surgery.

Downloaded for Anonymous User (n/a) at Egyptian Knowledge Bank from ClinicalKey.com by Elsevier on March 10, 2024. For personal use only. No other uses without permission. Copyright ©2024. Elsevier Inc. All rights reserved.

TREATMENT OF HYPERHIDROSIS					
	Therapy	**Frequency & recommended dose**	**Side effects**	**Duration**	**Comments**
First-line	Topicals Aluminum chloride hexahydrate – 6.25% to 20% Aluminum chloride – 12% to 20% Aluminum sesquichlorohydrate – 15% Aluminum zirconium salts	Use nightly for 3–5 nights, then every few days as needed	Burning Irritant contact dermatitis	Days	Blocks sweat ducts Aluminum zirconium salts may be effective in axillae, but not volar surfaces
	Glycopyrronium cloth, 2.4%	At bedtime, one cloth applied to both axillae that are clean and dry	Local: erythema, burning, pruritus Systemic: dry mouth > mydriasis > urinary hesitation, blurred vision	Hours	Anticholinergic* Washing hands immediately after application avoids inadvertent eye exposure
	5% sofpironium gel	Daily			
Second-line	*Acetylcholine release inhibitors, i.e. botulinum toxins*	Every 4–6 months	Discomfort during injection Weakness of underlying muscles	Months	Prevents release of acetylcholine from neurons
	Iontophoresis	2–3 times a week	Discomfort during procedure	Days	Blocks sweat ducts
	Oral therapy†	As needed		Hours	
	Oxybutynin‡	1.25–5 mg daily - BID (IR) 5–15 mg daily (ER)	Dry mouth and urinary retention most common; also confusion and decreased mental status		Anticholinergic*
	Glycopyrrolate‡	1–2 mg BID - TID			Anticholinergic*
	Nifedipine XL	30 mg once daily with escalation to 90 mg once daily	Headache, flushing, ankle edema, hypotension		Calcium channel blocker
	Clonidine	0.1–0.3 mg BID	Hypotension, rebound hypertension		α_2-Adrenergic agonist
	Propranolol	10–40 mg BID	Hypotension, bradycardia, hyperhidrosis with long-term use		β-Adrenergic blocker
	Clonazepam	0.25–0.5 mg BID	Sedation		Anxiolytic
	Thermal ablation Nd:YAG laser Microwave thermolysis	Multiple	Expensive	Years	
Third-line	*Liposuction*	Once to more than once¶	Expensive	Semipermanent to permanent	
	Local excision	Once	Scarring	Permanent	Last resort
	Sympathectomy	Once	Compensatory hyperhidrosis Horner syndrome	Usually permanent	

*Contraindications to topical and oral anticholinergics include glaucoma, urinary retention, paralytic ileus or toxic megacolon, and myasthenia gravis.
†Combined with topical therapy.
‡A link between long-term use of oral anticholinergic medications and development of dementia has been reported.
¶May need to be performed more than once to treat glands that have regenerated or were missed.

Table 39.7 Treatment of hyperhidrosis. Examples of topical commercial products are Xerac® AC, Drysol®, and Driclor® (6.25%, 20%, and 20% aluminum chloride [AlCl] hexahydrate, respectively), Certain-Dri® (12% AlCl), and Carpe® lotion (aluminum sesquichlorohydrate 15%). Lumē is an aluminum-free product that can be used anywhere on the body. Ingredients in alternative aluminum-free products include baking soda, corn starch, tapioca starch, kaolin clay, candelilla wax, zinc oxide, and fragrances. BID, twice daily; ER, extended release; IR, immediate release; TID, three times daily.

Sympathectomy is the last resort for patients with volar hyperhidrosis. Advances in endoscopic surgery have decreased the morbidity associated with this procedure. Sympathectomy at the T2–T3 level for palmar disease and the lumbar area for plantar disease is effective. Risks of the procedure include Horner syndrome, hypotension, and pneumothorax. Compensatory hyperhidrosis of the trunk or gustatory facial sweating may occur[26] and the hyperhidrosis may gradually recur.

HYPOHIDROSIS AND ANHIDROSIS

Key features

- An inability to sweat can be life-threatening due to the development of heat-related illnesses
- Causes of hypo- and anhidrosis include central or neuropathic disruption of neural impulses, sweat gland abnormalities, and medications

Three major categories of disorders are recognized causes of anhidrosis: (1) central and neuropathic diseases or medications that disrupt neural impulses from the anterior hypothalamus to the eccrine gland; (2) peripheral (non-neural) alterations in the gland itself; and (3) idiopathic.

Central and Neuropathic Hypohidrosis

Disturbance or interruption of innervation at any level, from the sweating centers in the brain down through the descending neural tracts to the sweat glands, can result in decreased or absent sweating. Causes are listed in Table 39.8. Pontine or medullary lesions lead to unilateral facial anhidrosis on the ipsilateral side of the face and neck. Fiber tracts carrying sudomotor neurons to lower levels in the spinal cord are both crossed and uncrossed and the resultant anhidrosis of the skin may be ipsi- or contralateral.

Both peripheral neuropathies and degenerative neurologic disorders can cause anhidrosis. Chronic orthostatic (postural) hypotension may be associated with decreased sympathetic innervation of the sweat glands, and syncopal episodes in these patients are not accompanied by sweating.

Downloaded for Anonymous User (n/a) at Egyptian Knowledge Bank from ClinicalKey.com by Elsevier on March 10, 2024. For personal use only. No other uses without permission. Copyright ©2024. Elsevier Inc. All rights reserved.

CAUSES OF CENTRAL AND NEUROPATHIC HYPOHIDROSIS AND ANHIDROSIS

• Tumors, infarctions, and other lesions of the hypothalamus, pons, or medulla
• Spinal cord tumors and injuries
• Horner syndrome
• Degenerative syndromes
  • Pure autonomic failure
  • Multiple system atrophy (Shy–Drager syndrome)*
  • Ross syndrome (see text)
• Autoimmune autonomic neuropathy
• Congenital insensitivity to pain with anhidrosis
• Peripheral neuropathy due to:
  • Diabetes
  • Alcoholism
  • Leprosy
  • Amyloidosis (immunoglobulin light chain and transthyretin types)
• Drugs (see Table 39.9)

*Progressive autonomic dysfunction, parkinsonism, and ataxia.

Table 39.8 Causes of central and neuropathic hypohidrosis and anhidrosis.

This is in contrast to the sweating, pallor, and nausea seen in common vasodepressor fainting.

Ross syndrome, which consists of Adie syndrome (myotonic pupils and absent deep tendon reflexes) plus segmental anhidrosis that is typically associated with compensatory hyperhidrosis, also falls into this group. Congenital insensitivity to pain with anhidrosis (hereditary sensory and autonomic neuropathy type IV) is a rare autosomal recessive disorder which presents with recurrent fevers due to anhidrosis, self-mutilation due to insensitivity to pain, and intellectual disability. Mutations in *NTRK1*, which encodes the tyrosine kinase receptor for nerve growth factor, have been detected in these patients. Skin biopsy specimens reveal a lack of innervation of eccrine sweat glands.

Disruption of the superior cervical ganglion results in Horner syndrome, and chemical blockade of selected sympathetic ganglia will result in regional anhidrosis. Any drug that interrupts synaptic transmission in autonomic ganglia will suppress sweating (Table 39.9).

DRUGS THAT CAUSE HYPOHIDROSIS AND ANHIDROSIS	
Blockade of neurotransmission	
Nicotinic acetylcholine receptor antagonists (ganglion-blocking agents)	
• Hexamethonium • Mecamylamine	• Tetraethylammonium • Trimethaphan
Muscarinic acetylcholine receptor antagonists*	
• Atropine • Glycopyrrolate	• Oxybutynin • Scopolamine
Calcium channel blockers	
α-Adrenergic blockers • Phenoxybenzamine (hypohidrosis occasionally observed) • Phentolamine†	
α_2-Adrenergic agonists‡ • Clonidine	
Dysfunction or destruction of the eccrine gland¶	
• Aldehydes (topical) • Aluminum salts (topical) • 5-Fluorouracil • Quinacrine	• Topiramate§ • Zirconium salts (topical) • Zonisamide§
*Antipsychotic drugs (e.g. phenothiazines), tricyclic antidepressants, and some antihistamines can also have anticholinergic effects, especially when administered in combination and at high doses. †Thought to suppress eccrine sweating by inhibiting ganglionic transmission. ‡Decrease sympathetic outflow from the CNS. ¶Eccrine gland necrosis is also a feature of coma bullae, which are classically associated with barbiturate overdose but can also be observed in comas induced by other drugs (see Ch. 33); syringosquamous metaplasia may result from the toxic effects of chemotherapeutic agents (e.g. cytarabine, doxorubicin) on the eccrine glands. §Decreased sweating has been attributed to inhibition of carbonic anhydrase isoenzymes in the eccrine glands.	

Table 39.9 Drugs that cause hypohidrosis and anhidrosis. Refers to systemic administration unless otherwise indicated.

Peripheral Anhidrosis

Congenital and acquired alterations or disturbances of the sweat glands result in an absence or significant reduction in sweating (Table 39.10). Hypo- or anhidrosis is one of the clinical findings in several types of ectodermal dysplasia[30]. In patients with ichthyoses, obstruction of sweat ducts can lead to hypohidrosis.

The skin of elderly individuals may show some atrophy of the sweat glands, but overall they are preserved and continue to function with advancing age. Toxic and thermal insults to the skin and a variety of inflammatory and neoplastic disorders can destroy or produce atrophy of the sweat glands (see Table 39.10).

Diagnosis of Anhidrosis

Heat intolerance may be due to a number of underlying disorders. New symptoms such as drowsiness, fatigue, or inability to concentrate in hot environments in association with a decrease in the patient's "normal sweating" point to acquired hypo- or anhidrosis. A careful history will yield clues to the diagnosis, with special attention to new medications, recent medical events (e.g. a cerebrovascular accident), the presence of diabetes or other chronic conditions, and family history (see Tables 39.8–39.10).

Examination of the patient's skin may not reveal the presence or extent of anhidrosis. A hot environment or exercise may be required but excessive overheating must be avoided. Colorimetric or gravimetric testing (see above) and infrared thermography will demonstrate diminished or absent sweating. Local intradermal injection of cholinergic drugs to stimulate sweating in small areas can also be utilized, but the risk of side effects generally precludes their injection into large areas. Testing for axon reflex sweating with intradermal nicotine sulfate or picrate in appropriate doses (e.g. 0.001 mg) or administration of acetylcholine via iontophoresis may be performed in patients in whom peripheral neuropathies are suspected.

PERIPHERAL CAUSES OF HYPOHIDROSIS AND ANHIDROSIS DUE TO SWEAT GLAND ABNORMALITIES
Genetic disorders

• Ectodermal dysplasias
  • Hypohidrotic ectodermal dysplasia
  • Hypohidrotic ectodermal dysplasia with immune deficiency
  • Rapp–Hodgkin syndrome
  • Naegeli–Franceschetti–Jadassohn syndrome
• Incontinentia pigmenti
• Bazex–Dupré–Christol syndrome
• Fabry disease*

Destruction
• Tumors (e.g. lymphoma) • Burns • Radiation therapy, including electron beam therapy • Systemic sclerosis (scleroderma) and morphea • Sjögren syndrome† • Graft-versus-host disease • Acrodermatitis chronica atrophicans
Obstruction
• Miliaria • Ichthyoses (e.g. lamellar ichthyosis) • Psoriasis • Eczematous dermatoses • Bullous diseases (e.g. epidermolysis bullosa [inherited or acquired]) • Porokeratosis
*Hyperhidrosis (related to autonomic dysfunction) can also occur. †Hypohidrosis can also result from peripheral neuropathy.

Table 39.10 Peripheral causes of hypohidrosis and anhidrosis due to sweat gland abnormalities.

Downloaded for Anonymous User (n/a) at Egyptian Knowledge Bank from ClinicalKey.com by Elsevier on March 10, 2024. For personal use only. No other uses without permission. Copyright ©2024. Elsevier Inc. All rights reserved.

Finally, a biopsy specimen from an affected area of skin should be obtained in virtually all patients with anhidrosis to identify sweat gland abnormalities. When possible underlying etiologies have been excluded (see Tables 39.8–39.10), acquired idiopathic generalized anhidrosis should be considered (Table 39.11)[31,32].

Treatment of Anhidrosis

Treatment options for anhidrosis are limited. Offending medications should be discontinued. Keeping the patient in a cool environment is essential. For disorders due to clogged sweat ducts, gentle exfoliation may be helpful. Disorders of cornification (e.g. lamellar ichthyosis) associated with overheating should be treated aggressively. Use of water-containing spray bottles can prove useful.

ABNORMALITIES AND ALTERATIONS OF ECCRINE AND APOCRINE SWEAT COMPOSITION

Key features

- Some disorders (e.g. cystic fibrosis) lead to abnormal chemical composition of sweat
- Eccrine bromhidrosis is most commonly caused by maceration of the stratum corneum and bacterial degradation of keratin
- Apocrine bromhidrosis is related to bacterial degradation of apocrine sweat
- Eccrine chromhidrosis is due to *exogenous* chemicals that color the sweat
- Apocrine chromhidrosis is usually due to *intrinsic* causes

Abnormalities of eccrine sweat composition, as evidenced by altered electrolyte content or the presence of other anomalous substances, are recognized as disorders of eccrine function. Some of these glandular disturbances are not accompanied by clinically distinctive signs or symptoms, whereas others result in well-defined clinical entities.

ACQUIRED IDIOPATHIC GENERALIZED ANHIDROSIS
Rare disorder of unknown etiology Acquired, broadly distributed reduction in sweat production
Reported primarily in Asian populations, especially Japanese Male predominance (~80%) Most commonly presents during the 2nd to 4th decade When widespread, heat intolerance or stroke may occur
Three subtypes: • Sudomotor neuropathy • Idiopathic pure sudomotor failure (most common form) • Sweat gland failure
Diagnostic features: • By thermoregulatory sweat testing (starch–iodine test), hypohidrosis or anhidrosis involves >25% BSA and is usually symmetric • Sweating is preserved on the face, palms, and soles and in the axillae • Exclusion of other causes (e.g. medications, neurologic disorders, cutaneous diseases, Sjögren syndrome; see Tables 39.8–39.10)
Additional findings in affected areas: • Decreased sweating following local injection of acetylcholine • No induction of sweating by QSART, which assesses sweating due to the axon reflex • Marked variation in histologic findings, from normal-appearing eccrine glands to eccrine gland atrophy or absence, occlusion of proximal ducts, and periglandular inflammatory infiltrates
Treatment: • Lifestyle guidance, i.e. avoid heat if possible • Oral medications: pulse corticosteroids, cyclosporine, antihistamines

Table 39.11 Acquired idiopathic generalized anhidrosis. BSA, body surface area; QSART, quantitative sudomotor axon reflex test (acetylcholine is administered to the skin via iontophoresis and then sweating is measured). See refs. 31 and 32.

Notable among this group of disorders are those in which there is altered electrolyte concentration in sweat (Table 39.12). Cystic fibrosis, an autosomal recessive disorder caused by mutations in the *c*ystic *f*ibrosis *t*ransmembrane conductance *r*egulator (*CFTR*) gene, is an important example in which all of the exocrine glands in the body are affected, leading to dysfunction of multiple organs, including the lungs, exocrine pancreas, intestines, and liver. Cystic fibrosis patients demonstrate decreased electrolyte reabsorption by the eccrine duct, which results in increased loss of sodium, chloride, and (to a lesser extent) potassium in sweat. Increased Cl^- concentration in sweat (>60 mEq/L on two separate occasions) remains the most widely used diagnostic assay for this disease; it is referred to as the sweat chloride test. Cystic fibrosis patients still produce sweat in response to heat and most pharmacologic stimuli, but the increased loss of electrolytes poses a systemic risk for them in hot environments. An absent or markedly diminished response of the eccrine glands and other exocrine glands to β-adrenergic agonists is another marker for this disorder, since the CFTR protein is a Cl^- channel activated via β-adrenergic stimulation.

Excretion of calcium in eccrine sweat has been demonstrated in patients with widespread idiopathic calcinosis cutis. In uremia, high levels of urea can produce a "uremic frost" on the skin of these seriously ill patients[33]; however, readily available dialysis has made this a rare finding. Decreased size of the sweat glands, the significance of which is unknown, has also been described in patients with uremia[34]. Many drugs, including opiates, amphetamines, anticonvulsants, antimicrobials (e.g. azole antifungals, griseofulvin), and chemotherapeutic agents, as well as metals such as copper and mercury have been shown to be secreted in sweat[35,36].

In healthy individuals, both eccrine sweat and apocrine sweat are odorless when they are secreted. Eccrine bromhidrosis can develop secondary to maceration of the stratum corneum with bacterial degradation of keratin; the odor emanates primarily from the feet and intertriginous zones, especially the inguinal region. In apocrine bromhidrosis, the odor reflects bacterial degradation of apocrine sweat into ammonia, volatile fatty acids, and thioalcohols. The types of bromhidrosis are listed in Table 39.13.

Malodorous sweat can also be caused by abnormal secretion of amino acids and their analogues or breakdown products. This occurs in several heritable metabolic disorders[37] (see Table 39.13). In addition, some foods such as garlic and asparagus can cause eccrine bromhidrosis.

Colored eccrine sweating (*eccrine* chromhidrosis) can result from hyperbilirubinemia (green), ingestion of certain foods (e.g. red due to cranberry juice), and dyes in drugs (e.g. yellow from tartrazine). Pseudochromhidrosis results from contamination of colorless eccrine sweat by pigment from microorganisms, including *Corynebacterium* spp. (blue, brown/black), *Serratia marcescens* (red/pink), *Pseudomonas*

SYSTEMIC DISORDERS THAT AFFECT THE LEVELS OF ELECTROLYTES IN SWEAT
Increased levels of electrolytes in sweat*

• Cystic fibrosis
• Endocrine disorders
  • Adrenal insufficiency (e.g. due to Addison disease or congenital adrenal hyperplasia)
  • Myxedema
  • Nephrogenic diabetes insipidus
• Familial intrahepatic cholestasis
• Malnutrition
• Metabolic disorders
  • Fucosidosis
  • Glycogen storage disease type I
• Unacclimatized individuals exposed to heat

Decreased levels of electrolytes in sweat

• Endocrine disorders
  • Aldosteronism
  • Cushing syndrome
  • Thyrotoxicosis
• Hypoproteinemic edema (e.g. due to cirrhosis or nephrotic syndrome)

*Elevated sweat electrolytes (which may result in a false-positive chloride sweat test) can also be observed in patients with skin conditions such as widespread atopic dermatitis, ichthyosiform erythroderma, or ectodermal dysplasia.

Table 39.12 Systemic disorders that affect the levels of electrolytes in sweat.

Downloaded for Anonymous User (n/a) at Egyptian Knowledge Bank from ClinicalKey.com by Elsevier on March 10, 2024. For personal use only. No other uses without permission. Copyright ©2024. Elsevier Inc. All rights reserved.

TYPES OF BROMHIDROSIS
Apocrine
• Axillary (formation of thioalcohols by *Staphylococcus hominis* a major component)
Eccrine

• Keratinogenic
  • Plantar
  • Intertriginous
• Metabolic
  • Phenylketonuria (musty or "mousy" odor)
  • Maple syrup urine disease (sweet odor)
  • Methionine adenosyltransferase deficiency ("boiled cabbage" odor)
  • Methionine malabsorption syndrome (oasthouse syndrome; "beer-like" odor)
  • Trimethylaminuria ("fishy" odor)*
  • Dimethylglycine dehydrogenase deficiency ("fishy" odor)
  • Isovaleric acidemia ("sweaty feet" odor)
• Exogenous
  • Foods, e.g. garlic, asparagus, curry
  • Drugs, e.g. penicillins, bromides
  • Chemicals, e.g. dimethyl sulfoxide (DMSO)

*Exacerbated by eating marine fish, eggs, kidney, or liver.

Table 39.13 Types of bromhidrosis.

aeruginosa (blue-green), *Bacillus* spp. (blue), and *Malassezia furfur* (blue). Miners or workers in the copper industry often exhibit blue or blue–green sweat due to external deposits of copper salts. Sunless-tanning products can result in brown sweat. Hematidrosis (bloody sweat) has been reported periodically and appears to be associated with psychiatric disease. Red sweat has been described in patients receiving clofazimine and rifampin.

In contrast, *apocrine* chromhidrosis is usually intrinsic in origin and blue or black in color, resulting from the excretion in apocrine sweat of lipofuscin in large amounts or in a highly oxidized state. Chromhidrosis, primarily axillary in location and presumably of apocrine origin, can be seen in alkaptonuria and may be a presenting sign of the disease as the excreted pigment stains the undershirts of these patients.

DIAGNOSTIC MICROSCOPIC CHANGES IN ECCRINE SWEAT GLANDS

A variety of disorders display diagnostic microscopic findings within the eccrine sweat glands, ranging from intracellular inclusions and degenerative alterations to changes in the size of the glands or their components. Table 39.14 summarizes these distinctive histopathologic features, which may be overlooked in the diagnostic evaluation of patients. Most of the findings listed can be visualized by light microscopy. By electron microscopy, viral particles from Ebola virus and severe acute respiratory syndrome (SARS) have been found in eccrine sweat ducts[38]. Although there have been reports of SARS-CoV-2 being present in the sweat of infected individuals, more recent studies have failed to detect its secretion in sweat, with no evidence that sweat can serve as a source of transmission[39].

INFLUENCE OF SWEAT ON SKIN DISEASES

Key features

- Wet skin is more permeable than dry skin
- Wet skin is more likely to develop contact allergies than dry skin
- Several cutaneous diseases are aggravated by sweat

That wet skin is more permeable than dry skin has been clearly established, and skin wetted by perspiration is more likely to be sensitized to contact allergens. Damp skin is also more susceptible to absorption of toxic chemicals. The macerative effect of sweat is an essential early step in the pathogenesis of sweat retention syndromes, such as miliaria. Sweat-saturated keratin, upon bacterial degradation, gives rise to plantar bromhidrosis and pitted keratolysis. Softening of the skin by sweat facilitates the entry and growth of microbes, leading to flexural candidiasis, bacterial folliculitis, bullous impetigo, superficial dermatophyte infections, tinea versicolor, verrucae, and molluscum contagiosum. Grover disease, Darier disease, and Hailey–Hailey disease are clearly aggravated by sweating. Some systemic drugs, such as antifungal agents, are excreted in eccrine sweat and diffuse from the sweat ducts to the surrounding stratum corneum, exerting inhibitory effects on microorganisms.

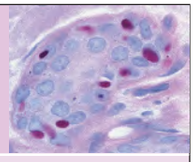

DIAGNOSTIC MICROSCOPIC CHANGES IN ECCRINE GLANDS	
Disorder	**Microscopic changes**
Exposures/metabolic	
Argyria	Granules in eccrine basement membrane (darkfield)
Chemotherapy (traditional)	Vacuolar degeneration of secretory cells and/or ducts; dense eccrinotropic infiltrate of neutrophils (may be sparse or lymphocytic in neutropenic patients)
Coma bullae	Necrosis of secretory cells and duct cells
Hypothyroidism	PAS-positive, diastase-resistant granules in secretory cells
Uremia	Reduced size of sweat glands
Tumors	
Mycosis fungoides, syringotropic	Dense infiltrate of atypical lymphocytes within and around eccrine glands, often with squamous syringometaplasia
Genetic disorders	
Acid maltase deficiency Adrenoleukodystrophy Mucopolysaccharidoses (e.g. Hurler, Hunter, Sanfilippo) and mucolipidoses	Membrane-bound vacuoles in secretory cells
Lafora disease	PAS-positive granules in outer layer of duct cells (inset)
Neuronal ceroid lipofuscinoses	Cytoplasmic inclusions in secretory cells
Sphingolipidoses (e.g. Fabry, Niemann–Pick, Sandhoff)	Lipid inclusions in secretory cells
Trisomy 13, 18 or 21	Differences in duct: secretory coil length
Viral infections	
Ebola hemorrhagic fever Severe acute respiratory syndrome (SARS)	Viral particles in lumen of sweat gland tubule

Table 39.14 Diagnostic microscopic changes in eccrine glands. (Inset: Lafora disease.)

ADDITIONAL DISORDERS OF THE ECCRINE SWEAT GLAND

Miliaria

Key features

- Sweat retention can be caused by obstruction of the eccrine duct at various levels
- Miliaria crystallina or sudamina (superficial ductal occlusion) – clear vesicles
- Miliaria rubra or prickly heat (intermediate ductal occlusion) – erythematous papules or pustules
- Miliaria profunda or mammillaria (deeper ductal occlusion) – white papules
- Common in neonates (whose eccrine sweat ducts are not fully developed) and adults living in hot, humid climates
- Resolves with relocation to a cool environment

Downloaded for Anonymous User (n/a) at Egyptian Knowledge Bank from ClinicalKey.com by Elsevier on March 10, 2024. For personal use only. No other uses without permission. Copyright ©2024. Elsevier Inc. All rights reserved.

THREE TYPES OF MILIARIA				
Type	**Location of obstruction**	**Cutaneous lesions**	**Patient population(s)**	**Most common locations**
Crystallina	Stratum corneum	Non-pruritic, clear, fragile, 1 mm vesicles	Neonates <2 weeks of age Children and adults in hot climates	Face and trunk (Fig. 39.8)
Rubra	Mid-epidermis	Pruritic, erythematous, 1–3 mm papules; may have pustules (miliaria pustulosa)	Neonates 1–3 weeks of age Children and adults in hot climates	Neck and upper trunk (Fig. 39.9)
Profunda	Dermal–epidermal junction	Non-pruritic, white, 1–3 mm papules	Adults in hot climates; often with multiple bouts of miliaria rubra	Trunk and proximal extremities

Table 39.15 Three types of miliaria.

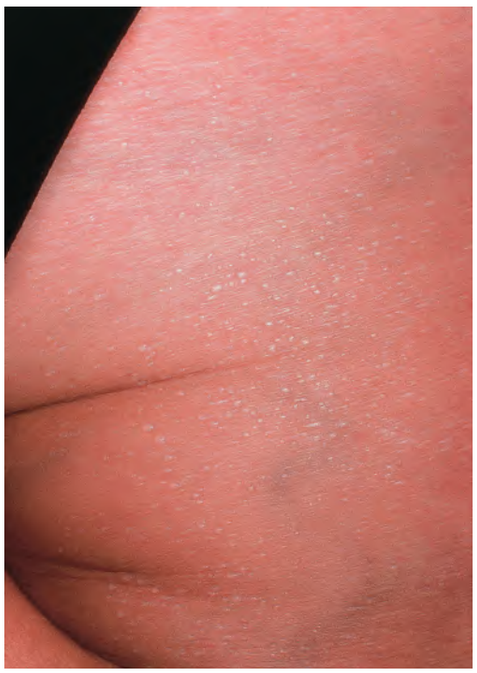

Fig. 39.8 Miliaria crystallina. Multiple small superficial vesicles with clear fluid.

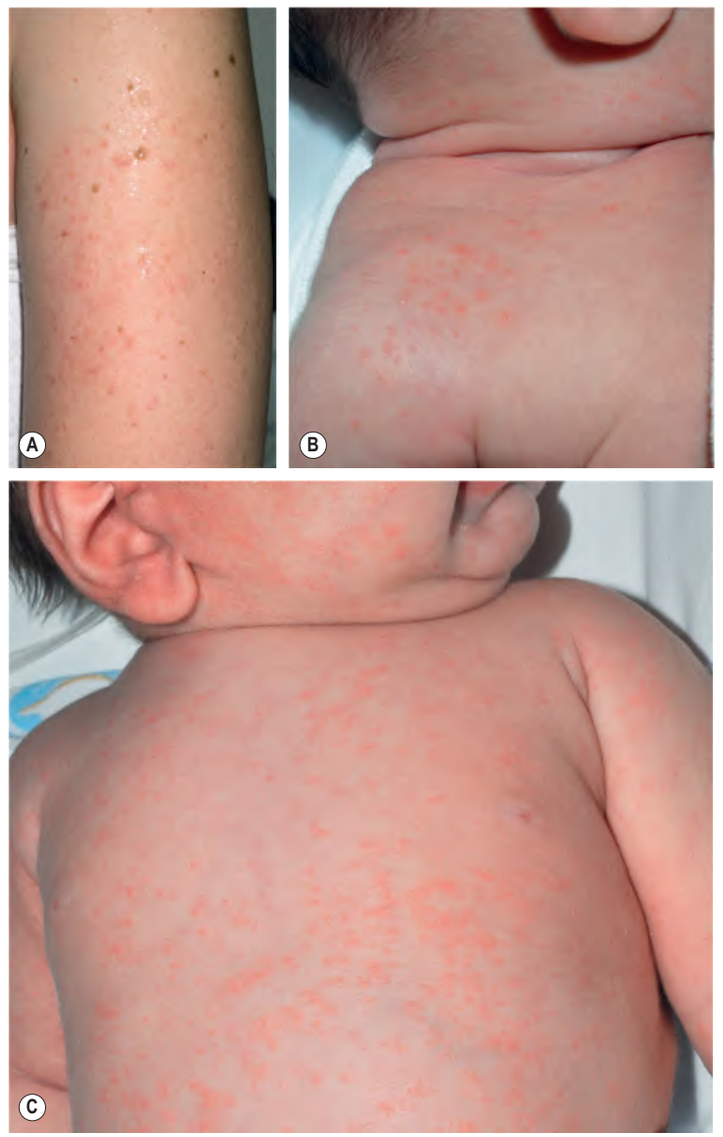

Fig. 39.9 Miliaria rubra. Multiple erythematous non-follicular papules and papulovesicles on the arm of an adult woman (**A**), on the upper trunk and neck of a neonate (**B**), and in a widespread distribution in an infant (**C**). In addition to obvious sweating, the woman also has a sunburn from recent sun exposure. Note that several of the lesions in the neonate have become pustular. *A, Courtesy Jennifer Powers, MD; B, Courtesy Julie V. Schaffer, MD; C, Courtesy Antonio Torrelo, MD.*

Miliaria encompasses a family of eccrine disorders all of which feature obstruction of the eccrine sweat duct. Three types are recognized, with each reflecting obstruction of sweat ducts at a different level, from the stratum corneum to the dermal–epidermal junction (Table 39.15). Blockage results in retention of sweat within the duct, causing a sweat retention vesicle to form.

Epidemiology and pathogenesis

Miliaria is most common in children, particularly neonates whose eccrine ducts are not fully developed. Congenital miliaria crystallina has even been described. Miliaria is also common in adults who live or work in very hot, humid environments. There is no racial or sex predisposition and it can occur in the elderly. Miliaria has not been associated with any specific underlying systemic disease.

Excessive sweating, particularly under occlusive clothing, can lead to maceration of the stratum corneum which is sufficient to cause blockage of the eccrine duct[30]. Keratinous plugs form, causing obstruction.

Clinical features

Each type of miliaria is clinically distinctive (see Table 39.15). *Miliaria crystallina* presents as small, clear superficial vesicles (Fig. 39.8) that rupture easily. It poses no systemic risk for the patient.

The most common form is *miliaria rubra*, which is characterized by small, non-follicular, erythematous macules and papules topped by a punctate vesicle (Fig. 39.9A,C). Lesions are usually pruritic and occasionally burn. Onset is within days to weeks of exposure to hot environments. Miliaria rubra may become pustular (Fig. 39.9B), especially in chronic, extensive cases. *Miliaria pustulosa*, as this variant is known, is sterile, although secondary bacterial infection may occur. Extensive cases of miliaria rubra can lead to hyperpyrexia.

When miliaria rubra is chronic or recurrent, occlusion may extend to a deeper level and produce *miliaria profunda*. Because of their deeper location, the sweat retention vesicles of miliaria profunda appear clinically as white papules, 1 to 3 mm in diameter. They start within minutes of initiation of sweating and subside within 1 to 2 hours after the sweating ceases. Lesions of miliaria profunda are asymptomatic. Only in those patients with concomitant miliaria rubra can pruritus or burning develop. When large numbers of sweat glands are occluded and essentially non-functional, these individuals are at risk for significant thermoregulatory problems and a compensatory hyperhidrosis of

Downloaded for Anonymous User (n/a) at Egyptian Knowledge Bank from ClinicalKey.com by Elsevier on March 10, 2024. For personal use only. No other uses without permission. Copyright ©2024. Elsevier Inc. All rights reserved.

the face is routinely observed (see Fig. 39.4A). Axillary and inguinal lymphadenopathy can also be seen, with resolution upon clearing of the miliaria. The term "tropical anhidrotic asthenia" has been applied to these patients.

Pathology

Biopsy specimens demonstrate ductal blockage. Keratinous obstruction of sweat ducts at the level appropriate for each type of miliaria may be seen, but several deeper sections may be required: in the stratum corneum for miliaria crystallina; the mid-epidermis for miliaria rubra; and at the dermal–epidermal junction for miliaria profunda. Sweat retention vesicles are seen underlying the respective sites of occlusion. Spongiosis in the vicinity of the epidermal sweat duct is common in miliaria rubra and miliaria profunda. Dermal inflammation is absent in miliaria crystallina, whereas perivascular lymphocytic infiltrates and vasodilation are evident in miliaria rubra. An eosinophilic cast can be seen occluding sweat ducts at the dermal–epidermal junction or intraepidermally in miliaria profunda. Periductal infiltration of lymphocytes is also seen along with mild focal spongiosis of the adjacent epidermis.

Differential diagnosis

The diagnosis is usually clinically apparent, but a simple diagnostic test consists of the puncture of a miliaria vesicle with a fine needle, resulting in release of the trapped clear sweat. In neonates, the differential diagnosis includes erythema toxicum neonatorum, neonatal cephalic pustulosis (which can involve the upper trunk as well as the face), candidiasis, and in atypical cases, other vesiculopustular diseases of the newborn (see Table 34.1). In adults, the differential diagnosis for miliaria rubra includes other conditions with a predilection for sites of occlusion and excessive sweating, such as folliculitis (with normal flora or *Staphylococcus aureus*), candidiasis, and Grover disease. The regression of miliaria profunda within hours of ceasing physical exertion and/or exposure to high temperatures distinguishes it from other papular eruptions.

Treatment

Management of all types of miliaria requires placement of the patient in a cool environment, in which sweating stops, for several days to weeks. Gradually, the obstructed sweat ducts shed their occluding keratinous plugs and normal sweating is restored. Topical anhydrous lanolin may dissolve the plugs in miliaria profunda. Anecdotally, other topicals (including corticosteroids and antibiotics) as well as oral antibiotics, retinoids, and vitamins A and C have been advocated as therapeutic options.

Multiple Sweat Gland Abscesses

Synonym: ▪ Periporitis staphylogenes

Key features

- Rare neonatal disorder
- Miliaria lesions become infected and form abscesses
- Most common on the neck, back, and buttocks
- May be associated with systemic symptoms

Multiple sweat gland abscesses represent a rare disorder of newborn infants that is likely due to a secondary staphylococcal infection of miliaria lesions. Malnourished or debilitated neonates are preferentially affected.

Clinically, erythematous papules and nodules are distributed on the occiput, neck, back, and buttocks. They are typically round or oval erythematous swellings that measure 1 to 2 cm in diameter and do not exhibit warmth, tenderness, or fluctuance. Lymphangitis and constitutional signs and symptoms such as fever and lassitude may occur with larger or more numerous lesions. Bacterial smears and cultures reveal *S. aureus*. Microscopically, abscess formation involving the sweat glands is seen.

The differential diagnosis includes furuncles or carbuncles and subcutaneous fat necrosis of the newborn. Although to date this disorder has not been associated with an immunodeficiency, primary immunodeficiencies (e.g. chronic granulomatous disease, hyper-IgE syndrome) should be considered in affected infants with recurrent cutaneous or extracutaneous infections. Systemic antibiotics, correction of the child's nutritional state, and elimination of factors encouraging the development of miliaria should be undertaken in the management of this condition.

Neutrophilic Eccrine Hidradenitis

Synonyms: ▪ Chemotherapy-associated eccrine hidradenitis ▪ Drug-associated eccrine hidradenitis

Key features

- Typically occurs following administration of chemotherapy
- Both children and adults can be affected
- Painful erythematous papules and plaques are classically found on the trunk
- Usually resolves within a few days to weeks

Epidemiology and pathogenesis

Neutrophilic eccrine hidradenitis (NEH) is a disorder of the eccrine sweat glands that occurs in both children and adults, but there may be a slight male predominance[40]. It was initially described in patients with acute myelogenous leukemia who had received cytarabine plus an anthracycline and this remains one of the most common clinical scenarios. NEH usually develops 7–14 days after initiating chemotherapy and can follow the administration of other chemotherapeutic agents including bleomycin, decitabine, and cyclophosphamide. It is generally regarded as a cytotoxic process directed at the sweat glands, e.g. via a direct toxic effect of chemotherapeutic drugs that are excreted in the sweat.

In addition, NEH has been reported after zidovudine treatment in HIV patients and following administration of granulocyte colony-stimulating factor, carbamazepine, TNF inhibitors, and targeted anti-cancer therapies including inhibitors of the epidermal growth factor receptor, KIT receptor, and BRAF[41]. In a small number of patients, NEH preceded and was believed to herald a new malignancy (usually acute myelogenous leukemia) or its relapse. An infectious form of NEH has also been described; most of the patients were immunocompromised, and the pathogenic organism (e.g. *Serratia, Enterobacter, S. aureus, Nocardia*) was often identified in tissue culture but not via light microscopy plus special stains of lesional specimens. Lastly, NEH has been observed in otherwise healthy persons.

Clinical features

Clinically, erythematous papules and plaques occur on the trunk and may also affect the extremities and face (Fig. 39.10). Polymorphic lesions, e.g. linear, annular, erythema multiforme-like, of varying sizes

Fig. 39.10 Neutrophilic eccrine hidradenitis. Erythematous plaques on the dorsal hand. *Courtesy Jeffrey P. Callen, MD.*

Downloaded for Anonymous User (n/a) at Egyptian Knowledge Bank from ClinicalKey.com by Elsevier on March 10, 2024. For personal use only. No other uses without permission. Copyright ©2024. Elsevier Inc. All rights reserved.

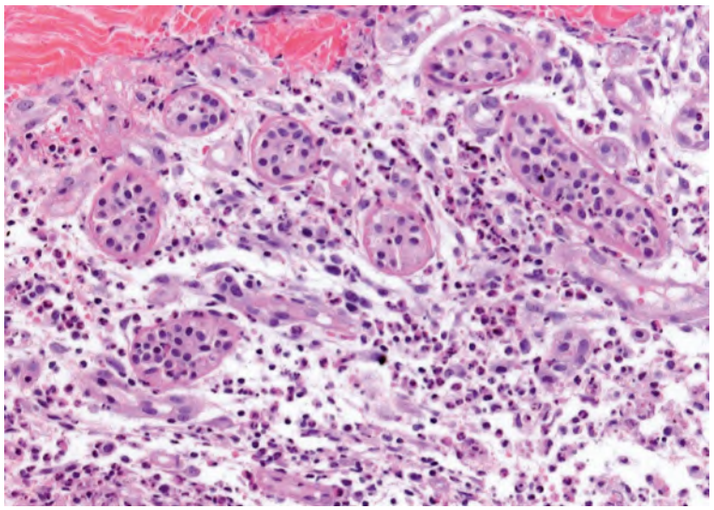

Fig. 39.11 Neutrophilic eccrine hidradenitis – histopathologic features. Neutrophils surround and infiltrate the eccrine glands and coils. There are degenerative changes of primarily secretory cells. *Courtesy Lorenzo Cerroni, MD.*

have been described, some of which were purpuric (typically in association with thrombocytopenia) or pustular. Patients are often febrile and neutropenic in the setting of chemotherapy-associated NEH.

Pathology

Histopathologic evaluation reveals eccrine sweat glands with degenerative vacuolar changes or even necrosis within secretory and (to a lesser degree) ductal cells; the process usually spares the acrosyringium. A neutrophilic inflammatory infiltrate classically accompanies these changes (Fig. 39.11). However, the infiltrate may be sparse or lymphocytic in the setting of chemotherapy-induced neutropenia. Squamous metaplasia of the cuboidal epithelial cells of the eccrine ducts, i.e. eccrine squamous syringometaplasia, is occasionally observed.

Differential diagnosis

The clinical differential diagnosis includes Sweet syndrome and infection, e.g. cellulitis, bacterial or fungal emboli. The histopathologic features of both NEH and eccrine squamous syringometaplasia can be seen in a number of chemotherapy-related entities including acral erythrodysesthesia and intertriginous eruption associated with chemotherapy. Toxic erythema of chemotherapy has been proposed as an overarching term for this spectrum of disorders[42] (see Ch. 21).

Treatment

The eruption of NEH is usually self-limited and resolves several days to weeks after cessation of chemotherapy, but may recur with subsequent cycles[34]. Because NEH usually arises in the setting of fever and neutropenia, empiric antimicrobial therapy is frequently administered until the possibility of infection is excluded. Corticosteroids seem to shorten the duration of the lesions and relieve the pain in some patients. Dapsone can be beneficial in treating NEH and preventing recurrences[42].

Idiopathic Palmoplantar Hidradenitis

Synonyms: ■ Palmoplantar eccrine hidradenitis ■ Recurrent palmoplantar hidradenitis

Key features

- Occurs primarily in otherwise healthy children
- Sudden onset of painful nodules on the palms and/or soles
- Resolves spontaneously within a few days to weeks, but may be recurrent

Fig. 39.12 Idiopathic palmoplantar hidradenitis. Erythematous papulonodules on the plantar surface. *Courtesy Michael L. Smith, MD.*

Idiopathic palmoplantar hidradenitis is primarily a disease of children and is not associated with any underlying medical conditions or medications[43]. Its onset is often preceded by vigorous physical activity. The proposed pathomechanism involves eccrine gland rupture due to mechanical and thermal trauma.

This disorder is characterized by the sudden onset of multiple, tender, erythematous nodules on the soles and less often the palms (Fig. 39.12). Neutrophilic infiltration of the secretory and ductal components of the coiled portion of the sweat glands is seen in biopsy specimens. This infiltrate is distinctly nodular, and neutrophilic abscesses may be observed. Eccrine squamous syringometaplasia is usually absent. The differential diagnosis includes the "pseudomonas hot-foot syndrome", panniculitis (e.g. erythema nodosum), pernio, and vasculitis (e.g. polyarteritis nodosa). Some have suggested that the entity "traumatic plantar urticaria" belongs within the spectrum of idiopathic palmoplantar hidradenitis.

Spontaneous resolution in a matter of days to weeks is the rule, although recurrent attacks occur in as many as half of affected children.

Granulosis Rubra Nasi

Key features

- Hyperhidrosis of the nose is followed by macular erythema; papules and vesicles can also develop
- The process may extend to the cheeks, lips, and upper chin
- Onset is during the first decade of life and usually resolves by puberty
- Autosomal dominant transmission

Granulosis rubra nasi is a rare inherited condition. It generally appears during childhood (peak incidence between ages 7 and 12 years), but adolescent or adult onset is possible. The etiology and pathogenesis of this disorder have not been elucidated. An autosomal dominant inheritance pattern has been described.

Hyperhidrosis of the tip of the nose may be present for years before the characteristic erythema develops on the nose; the latter can extend to the cheeks, chin, and upper lip. The entire area of erythema displays excessive sweating. Papules, sweat droplets, and vesicles may form at the orifices of the eccrine ducts. Cystic lesions can also develop and the nose may be cold. It may itch but is not painful. Primary hyperhidrosis of the palms and soles is a common concomitant finding, as is poor peripheral circulation with pernio or acrocyanosis. Granulosis rubra nasi usually resolves at puberty but may continue into adulthood.

Histopathologically, dilation of dermal blood and lymphatic vessels with mild inflammation around and within dilated sweat ducts (at times simulating a hidrocystoma) are seen. The epidermis, connective tissue, and pilosebaceous apparatus are otherwise normal and no heterotopic apocrine glands are found. No associated systemic disease or abnormal laboratory findings have been described.

The differential diagnosis includes rosacea, acne vulgaris, periorificial dermatitis, lupus pernio, and lupus erythematosus. Treatment can be disappointing and is limited to drying lotions, perhaps botulinum toxin injections or topical tacrolimus, and reassurance that the disorder typically resolves spontaneously at puberty.

Downloaded for Anonymous User (n/a) at Egyptian Knowledge Bank from ClinicalKey.com by Elsevier on March 10, 2024. For personal use only. No other uses without permission. Copyright ©2024. Elsevier Inc. All rights reserved.

Fig. 39.13 Keratolysis exfoliativa. Small annular collarettes of scale on the palm. *Courtesy Jean L. Bolognia, MD.*

Keratolysis Exfoliativa

Synonyms: ▪ Lamellar dyshidrosis ▪ Recurrent focal palmar peeling ▪ Dyshidrosis lamellosa sicca

Key features

- Superficial desquamation of the palms and occasionally the soles
- Non-inflammatory
- Treat with keratolytics

Keratolysis exfoliativa is a common, asymptomatic, superficial desquamative process of palmar and less often plantar skin; it usually worsens in warm weather and is occasionally associated with hyperhidrosis. Keratolysis exfoliativa is seen in healthy adults and possibly reflects low-grade damage to the thick stratum corneum of volar skin. Concurrent irritant dermatitis may also be present, and some cases may resemble or merge with pompholyx. Maceration may also be a pathogenic influence, although hyperhidrosis is not a regular feature.

Clinically, it appears as an irregular annular or circinate pattern of scaling, 2 to 15 mm in diameter (Fig. 39.13). There are no antecedent or concurrent vesicles or papules, and no fungi are recoverable from the lesions. Treatment is disappointing. Humectant and keratolytic topical products containing urea, ammonium lactate, or salicylic acid (5%–6%) may be helpful. Topical corticosteroids are not useful unless there is associated dermatitis.

Grover Disease (see Ch. 87).

DISORDERS OF THE APOCRINE SWEAT GLAND

Fox–Fordyce Disease

Synonym: ▪ Apocrine miliaria

Key features

- Caused by plugging of the apocrine sweat glands
- Occurs primarily in women 15–35 years of age
- Skin-colored follicular papules develop in the axillary, anogenital, and periareolar areas
- May be intensely pruritic

Epidemiology and pathogenesis

Fox–Fordyce disease is a chronic, pruritic disorder of the apocrine glands. It most commonly affects women between the ages of 15 and 35 years and usually remits after menopause.

Fig. 39.14 Fox–Fordyce disease. **A** Monomorphic skin-colored papules in the axillary vault, many of which are dome-shaped (inset). **B** Monomorphic hyperpigmented follicular papules with a central keratotic plug in the axillary vault. *A, Courtesy Jean L. Bolognia, MD; B, Courtesy Kalman Watsky, MD.*

The etiology of Fox–Fordyce disease is unknown, but hormonal factors are thought to play a role. Emotional and physical stimuli may also have a role in the disease course. It has occurred following the trauma of laser hair removal[44].

Clinical features

Fox–Fordyce disease presents as dome-shaped, skin-colored, discrete perifollicular papules within the axillary (Fig. 39.14), anogenital, and periareolar skin. Less common locations include the medial thighs, periumbilical area and sternal region. Loss of hair in affected areas is frequently observed. The condition is often intensely pruritic. Pregnancy and oral contraception may ameliorate the itching, while heat and emotional stress can aggravate symptoms.

Pathology

Early histologic findings of Fox–Fordyce disease include a keratin plug in the follicular infundibulum, which obstructs the entrance of the apocrine duct. This blockage leads to apocrine sweat retention and subsequent rupture of the duct at the level of the epidermis. Epidermal spongiosis and vesiculation are seen. Associated findings include a perifollicular and periadnexal mixed inflammatory infiltrate as well as perifollicular foam cells with PAS-positive cytoplasm, representing apocrine secretion material.

Treatment

Treatment of Fox–Fordyce disease is difficult. Topical and intralesional corticosteroids are often a first-line therapy, although their use may be limited by the risk of cutaneous atrophy. Topical calcineurin inhibitors may reduce pruritus and improve the appearance of skin lesions. Topical tretinoin has been shown to reduce pruritus, but has little effect on the clinical appearance of the disease and may produce irritation. Twice-daily clindamycin lotion may also be useful in minimizing symptoms. Some women respond to oral contraceptives, while other patients receive temporary relief from oral isotretinoin. Physical interventions that may be beneficial include phototherapy, electrocautery, and excision of periareolar skin.

Additional figures available in our eBook (see inside front cover for access code).

Downloaded for Anonymous User (n/a) at Egyptian Knowledge Bank from ClinicalKey.com by Elsevier on March 10, 2024. For personal use only. No other uses without permission. Copyright ©2024. Elsevier Inc. All rights reserved.

eFig. 39.1 Sweating pattern in axillary hyperhidrosis. Blue–black areas represent foci of sweating, as demonstrated by the starch–iodine technique: iodine solution (e.g. 3.5% in alcohol) is applied to clean, shaved skin and allowed to dry, then starch powder (e.g. cornstarch) is brushed onto the area. *Courtesy Harry Hurley, MD*.

eFig. 39.2 Miliaria rubra. Multiple erythematous non-follicular papules and papulovesicles on the back.

eFig. 39.3 Severe keratolysis exfoliativa. Annular and figurate collarettes of scale of varying size on the plantar surface. *Courtesy Kalman Watsky, MD*.

Downloaded for Anonymous User (n/a) at Egyptian Knowledge Bank from ClinicalKey.com by Elsevier on March 10, 2024. For personal use only. No other uses without permission. Copyright ©2024. Elsevier Inc. All rights reserved.